

# Diagnostic Dilemma in Ovarian Pregnancy: A Case Series

JASMINA BEGUM<sup>1</sup>, P.PALLAVEE<sup>2</sup>, SUNITA SAMAL<sup>3</sup>

## ABSTRACT

Ovarian pregnancy is a rare form of ectopic pregnancy but it is the most common type of nontubal ectopic pregnancy. Many times it is operated with a misdiagnosis of ruptured tubal ectopic pregnancy or hemorrhagic corpus luteum. The high resolution transvaginal ultrasonography is a valuable tool for diagnosis of ectopic pregnancy but ovarian pregnancy still remains a diagnostic problem and a continuous challenge to the gynecologist. The correct diagnosis is made at the time of surgery and confirmation is by histopathological report. Here we report three cases of primary ovarian ectopic pregnancies, consistent with the Spiegelberg's criteria. Out of this, two cases have corroboration of ovarian ectopic pregnancy with use of intrauterine contraceptive device and one case by chance without any preexisting risk factors, probably due to interference in the release of ovum from the follicle. In all the three cases, emergency laparotomy was done for ruptured tubal ectopic pregnancy and the diagnosis of ruptured primary ovarian pregnancy was made at the time of surgery, this was subsequently confirmed by histopathology report.

In the era where wider usage of intrauterine devices, ovulatory drugs and assisted reproductive techniques are rife, there is a possibility of an increase in the incidence of this rare entity, so ovarian ectopic pregnancy should be kept in mind as a possibility. Thereby early diagnosis by high resolution transvaginal ultrasound and laparoscopy can decrease the risk of complications like rupture, secondary implantation, hemorrhagic shock and maternal mortality.

**Keywords:** Contraceptive IUD, Ectopic pregnancy, Ovulatory dysfunction

## INTRODUCTION

Ectopic pregnancy is an important health problem and accounts for 10% of all maternal mortality. Incidence of ovarian pregnancy in natural conception vary from one in 7,000 to one in 40,000 deliveries and accounts for <3% of all ectopic pregnancies [1]. Ovarian pregnancy is classified into primary and secondary, the former is usually due to ovulatory dysfunction, where fertilization takes place within the follicle, where as the later is due to tubal abortion or perforation of the conceptus with ovarian stromal implantation. Ovarian pregnancy can again be as intrafollicular and extrafollicular types, intrafollicular is mostly primary but extrafollicular type can be either primary or secondary [2]. Here, we present three cases of primary ovarian ectopic pregnancy one case by chance without any preexisting risk factors, probably due to interference in the release of ovum from the follicle and two cases following use of contraceptive IUD.

## CASE REPORT

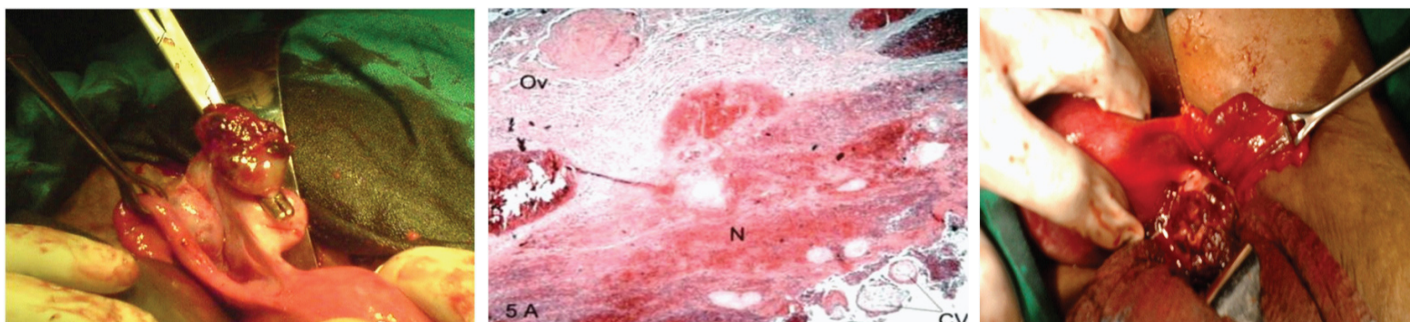
### Case 1

A 23 years old lady, G2P1L1, presented to us at six weeks four days of pregnancy with complaints of bleeding per vagina and lower abdominal pain. Obstetric history wise, she had delivered a full term baby five years back by lower segment caesarean section and was using contraceptive IUD for contraception which was removed recently and replaced by a new contraceptive IUD one month back. Following which she had bleeding per vagina and severe abdominal pain before her expected date of menstruation. Subsequently, urine pregnancy test was done which was positive and she underwent removal of the contraceptive IUD. Past medical and surgical history was uneventful. Her general condition was stable. On abdominal examination, right longitudinal paramedian scar of lower segment caesarean section was present, abdomen was soft with tenderness at right iliac fossa and hypogastrium, no guarding, rigidity and rebound tenderness was present. On per speculum examination

bleeding was present through os and on per vaginal examination uterus was anteverted, bulky, soft and cervical motion tenderness was present. Right fornix was tender but no adnexal mass was felt and the left fornix appeared to be free and nontender. A transvaginal scan, showed a right adnexal gestational sac with free fluid in cul-de-sac, with no evidence of intrauterine pregnancy. With the diagnosis of ruptured tubal ectopic pregnancy she was taken up for emergency laparotomy. Intraoperatively the fallopian tubes, uterus, right uterovarian ligament and the left ovary were normal. There were no signs of tubal abortion. The right ovary was enlarged with an organized clot of 3 cm × 3 cm size at the ruptured site [Table/Fig-1]. Hence we proceeded with a wedge resection with removal of all the hemorrhagic mass on right ovary. The diagnosis of primary ovarian pregnancy was confirmed by the histopathologist, who reported the specimen as a mass with hemorrhagic necrotic area showing chorionic villi, trophoblastic cells and ovarian stroma [Table/Fig-2].

### Case 2

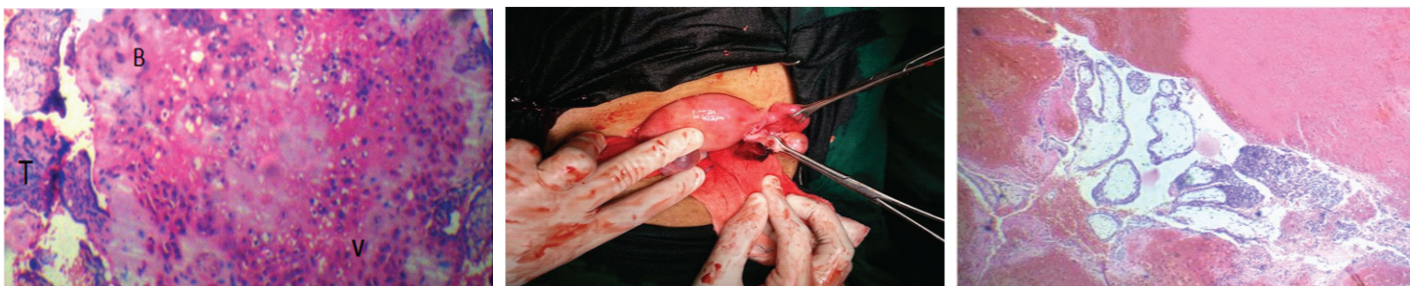A 27 years old lady, G2P1L1 presented to us in outpatient department with bleeding per vagina, severe abdominal pain and weakness at 8 weeks of pregnancy. She gave history of contraceptive IUD use for the last 18 months, which was removed two weeks after her confirmation of pregnancy. Since the day of contraceptive IUD removal, she had vaginal bleeding with severe pain abdomen and weakness. On examination her general condition was stable. Abdominal examination revealed right iliac fossa tenderness, however there was no guarding, rigidity or rebound tenderness. On per speculum examination, bleeding was present through os and on per vaginal examination uterus was anteverted, bulky, soft, and a tender adnexal mass of 4 cm × 4 cm felt on the right side, the left adnexa appeared to be free and nontender and cervical motion tenderness was also present. Transvaginal scan showed no evidence of intrauterine pregnancy. The right adnexa had a well circumscribed gestational sac suggestive of an ectopic pregnancy and minimal free fluid in cul-de-sac. She was taken up for laparotomy



**[Table/Fig-1]:** Intraoperative photograph of primary ovarian pregnancy held with artery forceps with normal tube

**[Table/Fig-2]:** Histopathological finding of ovarian pregnancy (hematoxylin eosin stain). Chorionic villi (CV) are evident in ovarian stroma (Ov) at magnification of 100 X

**[Table/Fig-3]:** Intraoperative photograph of primary ovarian pregnancy with normal tube and uterus (held with fingers)



**[Table/Fig-4]:** Histopathological finding of ovarian pregnancy . Gestational trophoblastic tissue with blood clot (B), vascularised chorionic villi (V) and trophoblastic hyperplasia (T). H&E stain, 100X

**[Table/Fig-5]:** Intraoperative photograph of primary ovarian pregnancy and the normal tube each held with Babcock's forceps

**[Table/Fig-6]:** Histopathological finding of ovarian pregnancy (H&E stain). Chorionic villi are seen in ovarian stroma at magnification of 100 X

immediately and intraoperatively there was an organized clot of size 6 cm in the cul-de-sac, both the fallopian tubes and the left ovary was normal. There were no signs of tubal abortion. The right ovary was enlarged with a haemorrhagic mass of 4 cm x 3 cm size [Table/Fig-3]. Hence we proceeded with a wedge resection and removal of all the haemorrhagic mass on right ovary. The diagnosis of primary ovarian pregnancy was confirmed after getting the histopathology report which showed a mass with haemorrhagic and necrotic areas containing chorionic villi, trophoblastic cells and ovarian stroma [Table/Fig-4].

### Case 3

A 29 year old lady, G4P2L1A1, presented with severe abdominal pain, and five episodes of vomiting for one day duration. Her last menstrual period was twenty two days before her admission without any history of amenorrhea and her previous menstrual cycles were regular. She gave a history of two vaginal deliveries with one preterm baby who did not survive, and second, a term baby which is alive and healthy. In third pregnancy she went for induced abortion for anomalous fetus at nineteen weeks of gestation, which was six months before her admission. Her postabortal period was uneventful. There was no history of intrauterine device use, tuberculosis, endometriosis, pelvic inflammatory disease, or any intake of fertility therapies. On examination, she was pale, having tachycardia, with abdominal distension, tenderness and shifting dullness. Per speculum examination was normal and on bimanual examination the uterus was soft and bulky, right fornix tenderness and cervical motion tenderness were also present. Her urine pregnancy test was positive, and ultrasonography showed a normal empty uterus and left adnexa. In right adnexa a well defined hypoechoic cystic lesion measuring 1.98 cm, having echogenic wall with minimal vascularity, corresponding to five week gestation with haemoperitoneum. Ruptured tubal ectopic pregnancy was diagnosed and emergency laparotomy was performed. The operative findings revealed ruptured right side ovarian pregnancy with haemoperitoneum [Table/Fig-5]. Rupture was seen on medial surface of ovary and remaining ovarian tissue was having cystic areas. Bilateral fallopian tubes and left side ovary was normal. There was no evidence of endometriosis or chronic inflammation in the pelvis. We did a salpingo-oophorectomy on the right side and the specimen was sent for histopathology.

She is under follow up in our outpatient department. The diagnosis of primary ovarian pregnancy was confirmed by histopathology report. Microscopic examination revealed ovarian tissue composed of corpus luteum, corpus albicans and corpus haemorrhagicum with chorionic villi surrounded by both viable and necrotic decidual cells and ovarian stroma [Table/Fig-6]. Section studied from the tube showed normal histology.

### DISCUSSION

Primary ovarian pregnancy is a rare entity. There has been an increase in the incidence of ovarian pregnancy due to better diagnostic modalities, wider use of contraceptive IUD, ovulatory drugs, and assisted reproductive techniques like invitro fertilization, embryo transfer and empty follicle syndrome. Endometriosis and pelvic inflammatory disease has also been implicated in the increasing incidence [1]. The diagnosis is difficult and a continuous challenge to the gynecologist. Many times it is misdiagnosed clinically and sonologically as ruptured tubal ectopic pregnancy, corpus luteum cyst, hemorrhagic cyst and chocolate cyst of ovary. Even it is difficult to differentiate ovarian pregnancy from haemorrhagic ovarian cyst at the time of surgery. Hallet (1982) in his study of 25 cases of ovarian pregnancies reported that a correct surgical diagnosis was only made in 28% of cases. In the remaining cases the pathologist made the diagnosis [3]. The diagnosis is quite difficult before surgery because the clinical presentations are similar to those of tubal pregnancy wherein both may have amenorrhea, irregular vaginal bleeding, abdominal pain and adnexal mass. It may be important to note that ovarian pregnancy can terminate several days before the expected date of menstruation without any history of amenorrhea. Rimdusit reported ten cases of ovarian pregnancy out of which six had no amenorrhea and the same thing was observed in our first and third case [4]. History of recent use of contraceptive IUD with extra uterine pregnancy should be viewed with suspicion towards probability of an ovarian pregnancy this was supported by a report revealed by Razeiel et al., that 90% of ovarian pregnancy occurred in contraceptive IUD users [5].

Lehfeldt in his study stated that contraceptive IUD prevents intrauterine implantation in 99.5%, tubal implantation in 95% and none at all in ovary, this was observed in our first and second case

[6]. In the third case, we could not obtain any history related to risk factors for ovarian pregnancy such as pelvic inflammatory disease, contraceptive IUD insertion, and fertility therapies. Intraoperatively there was no evidence of endometriosis and chronic pelvic infection, so here it can be hypothesized that the primary ovarian pregnancy took place due to interference in the release of ovum from the ruptured follicle and subsequently increased the risk of intrafollicular pregnancy. The diagnosis can sometimes be made before rupture by the use of high resolution transvaginal ultrasonography followed by diagnostic laparoscopy. Presumptive diagnosis of ovarian pregnancy can be made based on the positive quantitative  $\beta$  HCG without an intrauterine gestation, with presence of sonographic finding of a wide echogenic ring with an internal echo lucent area on the ovarian surface. The echogenicity of the ring is usually greater than that of the ovary itself, compared to a thin tubal ring with tubal pregnancies or corpus luteum cyst. A yolk sac or embryo was less commonly seen as progression beyond early stages is exceptional [7,8]. Other sonographic finding like complex adnexal masses or solid cystic masses with or without fluid in cul de sac, fluid surrounding the ovary and ovarian enlargement also result in high suspicion towards ovarian pregnancy [9]. Since all our the three cases were diagnosed as ruptured ectopic pregnancy and we were not sure of the site of pregnancy, so we proceeded for emergency laparotomy.

Early diagnosis and treatment is absolutely necessary to ensure a successful outcome. Seinere et al., concluded that laparoscopy is required for diagnosis and also for effective definitive surgical management at the same time [10]. In contrast to tubal ectopic pregnancy medical treatment by methotrexate has not been currently considered as a safe and successful treatment option. The mainstay of surgical treatment for ovarian pregnancy is oophorectomy or conservative surgical management like ovarian wedge resection depending on the extent of tissue destruction. Oophorectomy has been regarded unsuitable as preservation of ovary should be given precedence [11]. This is because the patients are generally fertile and the risk of recurrence is zero as no case of recurrent ovarian pregnancy has ever been documented. This is in contrast to tubal pregnancy which has approximately 15% recurrence [12].

All the three patients fulfil the criteria for diagnosis of ovarian pregnancy as outlined by Spiegelberg [13]:

- (1) The tube on the affected side should be intact separate from the ovary.
- (2) The gestational sac must be connected to the uterus by the utero-ovarian ligament.
- (3) The gestational sac should occupy the normal position of the ovary.
- (4) Definite ovarian tissue must be present in the gestational sac wall.

In our first and second case we did ovarian wedge resection and in our third case there was rupture at medial surface of ovary with massive hemoperitoneum and the lateral surface showed some cystic areas which after careful assessment for viability of ovarian tissue a unilateral salphingo-oophorectomy was done. In all the three cases the tubes were healthy and there were no signs of tubal abortion. Histologically, there was presence of chorionic villi and trophoblastic tissue in the ovarian tissue; hence a diagnosis of primary ovarian pregnancy was made in all our three cases.

## CONCLUSION

Ovarian ectopic pregnancy should be kept in mind as a rare possibility in females of reproductive age group presenting with acute abdomen, thereby early diagnosis by high resolution transvaginal ultrasound and laparoscopy will decrease the risk of rupture, secondary implantation, hemorrhagic shock and maternal mortality. It may also occur without a history of amenorrhea and any classical risk factors for ectopic pregnancy. Hence, it can be concluded that one has to be more vigilant when dealing with acute abdomen in females as it may have a bearing on future fertility.

## ACKNOWLEDGMENT

We are thankful to the patients for their consent to report the case history. We would also like to thank our colleagues in Department of Radiology and Department of Pathology, MGMC & RI, Puducherry for ultrasound reports and histopathology photomicrographs.

## REFERENCES

- [1] Das S, Kalyani R, Lakshmi V, Harendra kumar ML. Ovarian pregnancy. *Indian Journal Pathol Microbiol.* 2008; 51: 37-38.
- [2] Check JH, Chase JS. Ovarian pregnancy with contralateral corpus luteum. *Am J Obstet Gynecol.* 1986; 54: 155-56.
- [3] Hallett JG. Primary ovarian pregnancy: A report of twenty-five cases. *Am J Obstet Gynecol.* 1982; 143: 50-60.
- [4] Rimdusit P, Kastri N. Primary ovarian pregnancy and the intra uterine contraceptive device. *Obstet Gynecol.* 1976; 48: 57-59.
- [5] Hallett JG, Golan A, Pansky M, Ronel R, Bukovsky J, Capsi E. Ovarian pregnancy: a report of twenty cases in an institution. *Am J Obstet Gynecol.* 1990; 163: 1182-85.
- [6] Lehfeldt H, Tietze C, Gorstein F. Ovarian pregnancy and intrauterine device. *Am J Obstet Gynecol.* 1970; 108: 1005-09.
- [7] Comstoc C, Huston K, Lee W. The ultrasonographic appearance of ovarian ectopic pregnancies. *Obstet Gynecol.* 2005; 105(1): 42-45.
- [8] Ghi T, Banfi A, Marconi R, Iaco PD, Pillu G, Aloysio DD, Pelusi G. Three dimensional sonographic diagnosis of ovarian pregnancy. *Ultrasound Obstet Gynecol.* 2005; 26: 102-04.
- [9] Gupta N, Gupta A, Onyema G, Pantofel Y, Ying sc, Garon JE et al. Accurate preoperative diagnosis of ovarian pregnancy with transvaginal scan. *Case Rep Obstet Gynecol.* 2012; 2012: 934571.
- [10] Seinera P, Di Gregorio A, Arisio R, Decko A, Crane F. Ovarian pregnancy and operative laparoscopy report of eight cases. *Hum Reprod.* 1997; 12(3): 608-10.
- [11] Panda S, Darlong LM, Singh S, Borah T. Case report of a primary ovarian pregnancy in a primigravida. *J Hum Reprod Sci.* 2009; 2: 90-92.
- [12] Sergent F, Mauger-Tinlot F, Gravier A, Versyck E, Marpeau L. Ovarian pregnancies: reevaluation of diagnostic criteria. *J Gynecol Obstet Biol Reprod.* 2002; 31: 741-46.
- [13] Spiegelberg O. Zur casuistic der Ovarialschwangerschaft. *Arch Gynaekol.* 1878; 13: 73-79.

### PARTICULARS OF CONTRIBUTORS:

1. Associate Professor, Department of Obstetrics and Gynecology, Mahatama Gandhi Medical College and Research Institute, Puducherry, India.
2. Associate Professor, Department of Obstetrics and Gynecology, Mahatama Gandhi Medical College and Research Institute, Puducherry, India.
3. Associate Professor, Department of Obstetrics and Gynecology, Mahatama Gandhi Medical College and Research Institute, Puducherry, India.

### NAME, ADDRESS, E-MAIL ID OF THE CORRESPONDING AUTHOR:

Dr. Jasmina Begum,  
Associate Professor, Department of Obstetrics and Gynecology, Mahatama Gandhi Medical College and Research Institute,  
Pillaiyarkuppam, Puducherry -607402, India.  
E-mail : jasminaaly@gmail.com

FINANCIAL OR OTHER COMPETING INTERESTS: None.

Date of Submission: **Sep 29, 2014**  
Date of Peer Review: **Dec 07, 2014**  
Date of Acceptance: **Feb 05, 2015**  
Date of Publishing: **Apr 01, 2015**